

Case Report:

Oral pyogenic granuloma-a case report

¹Dr Mahesh Chavda, ²Dr Sushma Sanjay Lagdive , ³Dr Shefali Sharma

¹Professor & PG Guide, Dept. of Periodontics , G.D.C&H, Ahmedabad,Gujarat

²Associate Professor , Dept. of Periodontics , Siddhpur Dental College & Hospital, Gujarat

³Post Graduate student, Dept. of Periodontics , G.D.C&H,Ahmedabad,Gujarat

Corresponding author: Dr. Shefali Sharma

Date of submission: 12 September 2014; Date of Publication: 15 December 2014

Abstract:

Pyogenic granuloma(also known as a "Granuloma gravidarum," and "Pregnancy tumor") is a primarily oral disease which appears in the mouth as an overgrowth of tissue due to irritation, physical trauma or hormonal factors .The condition is frequently associated with periodontal pain and discomfort, in some cases interfering with mastication and creating esthetic problems. The name for pyogenic granuloma is misleading because it is not a true granuloma. The growth is typically seen in young adults, with occurrence in the oral cavity, especially the gingiva , this case report describes a pyogenic granuloma in a male patient, discussing the clinical features and histopathologic features and also the successful management of the lesion.

Keywords: pyogenic granuloma, gingiva, trauma

Introduction:

Pyogenic granuloma is a kind of inflammatory hyperplasia found in oral cavity considered to be non neoplastic in nature^{1, 2}. Hullihen³ was first to describe the case of pyogenic granuloma in English literature. In 1904, Hartzell⁴ gave the current term of "pyogenic granuloma" or "granuloma pyogenicum. Pyogenic granuloma also known as a "Eruptive hemangioma," "Granulation tissue-type hemangioma," "Granuloma gravidarum," "Lobular capillary hemangioma," "Pregnancy tumor" and "Tumor of pregnancy". Cawson et al.,⁵ in dermatologic literature have described it as "granuloma telangiectacticum" due to the presence of numerous blood vessels seen in histological sections.

The lesion appears as a result from local irritation, may be an exaggerated response to various stimuli such as low grade or chronic irritation, minor trauma, hormonal factors or drugs,

but in some cases there may be a hormonal conditioning factors, such as in the lesions occurring in pregnancy and at puberty.⁶ Pyogenic granuloma predominantly occurs in young females in the second decade of life, possibly because of a vascular effect due to hormonal changes⁷. The most frequent intraoral site is the gingiva (approximately 75%). It can also occur on the lips, tongue, buccal mucosa, palate and floor of the mouth⁸. It appears as an elevated, pedunculated or sessile mass with a smooth or lobulated surface. It is deep red or reddish-purple in colour, and the surface may be ulcerated. It also has tendency to bleed, either spontaneously or on provocation with slight trauma.

Differential diagnosis of pyogenic granulomas may include parulis, peripheral giant cell granuloma, peripheral ossifying fibroma, hemangioma, peripheral fibroma, leiomyoma, hemangioendothelioma, hemangiopericytoma,

bacillary angiomatosis, Kaposi's sarcoma, metastatic tumors, pregnancy tumor, and postextraction granuloma. Final diagnosis of pyogenic granuloma is made by histology of specimen after excisional biopsy. Corrective intervention of pyogenic granuloma is surgical excision with thorough scaling and curettage of the adjacent teeth and root surfaces. Because pyogenic granulomas are rarely encapsulated, they can recur if surgical removal is incomplete.⁹⁻¹⁰. Following case report presents a case of pyogenic granuloma in a male patient alongwith its histological findings and mode of treatment.

Case report

A 17 year old male patient reported to Government Dental College and Hospital, Ahmedabad with a chief complaint of difficulty in mastication and bleeding from gums during meals and toothbrushing due to swollen gum on the left side since 1 month. The patient was asymptomatic 1 month back and initially observed a tiny, bright-red nodule that bled profusely. The lesion then progressively increased to present size.

Medical history and the dental history was non contributory. Patient was a pan masala chewer since 3 years but has quit the habit from last 1 year and occasionally used toothpicks for cleaning the interdental spaces of teeth. There was no extraoral swelling present on left side of maxilla. The patient was afebrile and without lymphadenopathy. On intraoral examination the lesion was present on the facial aspects maxillary teeth spreading in the interdental area between 21 and 22 also covering more than 2/3rd of the facial aspect of 22 (FIG. 1). The lesion was tumorlike, nodular, lobulated, exophytic, manifested as red, erythematous surface with sessile base. The size of the lesion was 10 x 12 mm in diameter. On palpation the lesion was soft and compressible and bled easily on manipulation.

The oral hygiene status was fair. The presence of lesion made it difficult for the patient to carryout routine oral hygiene procedures leading to deterioration of the oral hygiene and thereby favouring the growth of the lesion. Width of attached gingiva was adequate. Intra-oral periapical radiograph revealed mild marginal bone loss. Blood examination revealed normal values.

Treatment

Oral prophylaxis was completed and the lesion was excised under aseptic conditions. Excision of the lesion up to and including the mucoperiosteum was carried out under local anesthesia using a scalpel and blade, followed by curettage and through scaling of the involved teeth (FIG.2). Periodontal dressing was placed and the patient was recalled after 1 week for removal of the pack and checkup (FIG.3). The excised tissue was sent to the Department of Oral Pathology for histologic examination.

Histological findings

covering the underlying connective tissue. The epithelium shows area of ulceration, the connective tissue was loose and highly vascular with budding endothelial capillaries & dense chronic inflammatory cell infiltrate. The connective tissue showed proliferating fibroblasts and collagen fibres interposed in which can be seen lot of epithelial lined spaces within the connective tissue can be seen patchy distribution of lymphocytes and plasma cells.(FIG. 4). Also there was no evidence of atypia or malignancy. The clinical and histopathological findings confirmed it to be a case of pyogenic granuloma.

Discussion

The pyogenic granuloma is a relatively common, tumor like, exuberant tissue response to localized irritation or trauma. Oral pyogenic granuloma show prominent capillary growth within a granulomatous mass rather than the real pyogenic organisms and

pus, so the term pyogenic granuloma is a misnomer and it is not a granuloma in the real sense.⁶ Pyogenic granulomas occur in all age groups, but are more frequently encountered in females in their second decade due to the increased levels of circulating hormones estrogen and progesterone. Yuan et al.,¹¹ concluded that the morphogenetic factors were higher in pyogenic granuloma rather than normal gingiva supporting the mechanism of angiogenesis in oral pyogenic granulomas in pregnant. However, the effects of female hormones on oral pyogenic granulomas were questioned by Bhaskar and Jacoway¹² since they found lesions both in males and females with no specific sex predilection.

In our case, patient discussed was 17 year old healthy male. Probable etiology in our case included calculus and repeated use of toothpick by patient and as discussed by Ainemo et al¹³ recurrent trauma causes release of various endogenous and angiogenic factors contributing to the increased vascularity of the lesion. These factors probably contributed to the development of this lesion.

Pyogenic granulomas can have a rapid growth pattern that can cause alarm. The maxillary gingiva (especially in the anterior region) is involved more frequently than the mandibular gingiva. The typical lesion involves the interproximal gingiva and increases in size to cover a portion of the adjacent teeth as seen in our case.(Fig-1). Pyogenic granulomas vary in size from a few millimeters to several centimetres, painless and soft to palpation.

Histologically, pyogenic granulomas are classified as the Lobular Capillary Hemangioma (LCH) type and the non-Lobular Capillary Hemangioma type.^{1,14} The LCH type has proliferating blood vessels organized in lobular aggregates, no specific changes such as oedema, capillary dilation or

inflammatory granulation were noted. The non-LCH type consisted of a vascular core resembling granulation tissue with foci of fibrous tissue. In the central area of the non-LCH pyogenic granuloma a greater number of vessels with perivascular mesenchymal cells non-reactive for alpha smooth muscle actin (SMA) is detected as compared with the lobular area of the LCH type pyogenic granuloma,

The biopsy report in this case report shows that the bulk of the lesion shows angiomatous tissue with endothelial cell proliferation, inflammatory cell infiltrate is seen in the form of few neutrophils, lymphocytes and plasma cells covered by parakeratinized epithelium [Fig-4] and confirmed the diagnosis of oral pyogenic granuloma of the LCH type as described.

Excision and biopsy of the lesion is the recommended line of treatment unless it would produce a marked deformity and in such a case incisional biopsy is recommended.¹⁵ Conservative surgical excision of the lesion with removal of irritants such as plaque, calculus and foreign materials is recommended for small painless non-bleeding lesions. Excision of the gingival lesions up to the periosteum with through scaling and root planning of adjacent teeth to remove all visible sources of irritation is recommended.¹ Various other treatment modalities such as use of Nd: YAG laser, carbon dioxide laser, flash lamp pulse dye laser, cryosurgery, electrodesiccation, sodium tetradecyl sulfate sclerotherapy¹⁴ and use of intra lesional steroids have been used by various clinicians. Powel et al¹⁶ reported the use of Nd:YAG laser for excision of pyogenic granuloma because of lower risk of bleeding as compared to other

techniques and superior coagulation characteristics.

In the present case, the lesion was surgically excised and was sent for histopathologic examination. The scaling and root planning of the adjacent teeth was completed to remove all the local irritants, which could have been the primary etiologic factor in the present case and patient was instructed not to use any interdental aid.

Treatment consideration during pregnancy is very important .It ranges from preventive measures such as careful oral hygiene, removal of dental plaque and use of a soft toothbrush. Wang et al recommended control of bleeding by desiccation of bleeders, firm compression of the lesion, use of blood transfusions in a case of severe bleeding from a pregnancy tumor and in rare cases termination of pregnancy due to uncontrollable eclampsia have been documented ¹⁷ . In some cases shrinkage of the lesion after pregnancy may make surgical treatment unnecessary ¹⁸ . However, if necessary treatment can be completed in the second trimester with follow-up of the case post-parturition ¹⁹ . Incomplete excision, failure to remove etiologic factors or repeated trauma contributes to recurrence of these lesions.⁶ Vilmann et al.² emphasized the need of follow-up, especially in pyogenic granuloma of the gingiva due to its much higher recurrence rate.

The present case was followed up for a period of 1 year and no recurrence was observed.

Conclusion

From the present case report it is concluded that pyogenic granuloma can be adequately treated with the correct diagnosis and proper treatment planning. A careful management of the lesion also helps in

preventing the recurrence of this benign lesion.

FIGURE-1

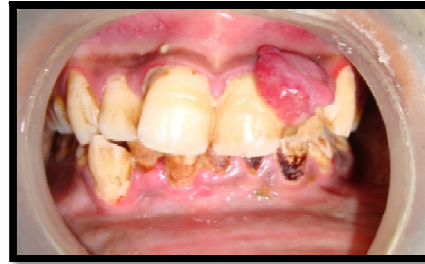

FIGURE-2

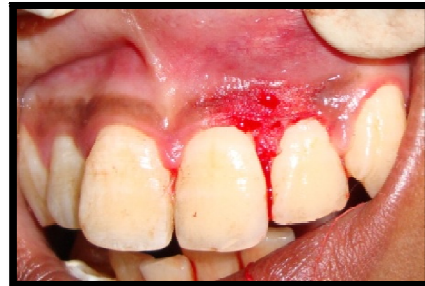

FIGURE-3

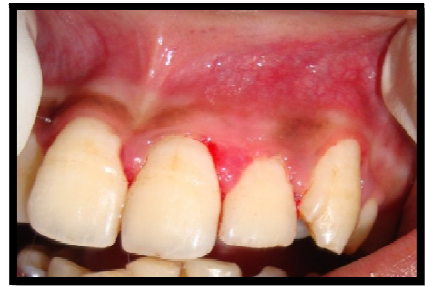

FIGURE-4

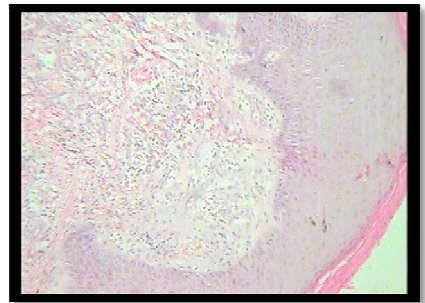


Figure 1- Pre surgical

Figure 2- After excision

Figure 3- Post surgical after one week

Figure 4- Histopathology

References

1. Neville BW, Damm DD, Allen CM, Bouquot JE. Oral and Maxillofacial Surgery. 2nd ed. Philadelphia: Saunders; 2002. p. 447-9.
2. Vilmann A, Vilmann P, Vilmann H. Pyogenic granuloma: Evaluation of oral conditions. Br J Oral Maxillofac Surg 1986;24:3
3. Hullihen SP. Case of aneurism by anastomosis of the superior maxillae. Am J Dent Sci 1844;4:160-2.
4. Hartzell MB. Granuloma pyogenicum. J Cutan Dis Syph 1904;22:520-5.
5. Cawson RA, Binnie WH, Speight PM, Barrett AW, Wright JM. Lucas Pathology of Tumors of Oral Tissues. 5th ed. Missouri: Mosby; 1998. p. 252-4
6. Regezi AJ, Sciubba J. Clinical pathologic correlations. 2nd ed. Philadelphia: WB Saunders Co; 1985. p. 194-6.
7. Jafarzadeh H, Sanatkhan M, Mohtasham N. Oral pyogenic granuloma: A review. J Oral Sci 2006;48:167-75
8. Parisi E, Glick PH, Glick M. Recurrent intraoral pyogenic granuloma with satellitosis treated with corticosteroids. Oral Dis 2006;12:70-2.
9. Shafer WG, Hine MK, Levy BM. A Textbook of Oral Pathology. Philadelphia: W.B. Sanders Company; 1983:359-361.
10. Angelopoulos AP. Pyogenic granuloma of the oral cavity; statistical analysis of its clinical features. J Oral Surg. 1971;29:840-847.
11. Yuan K, Jin YT, Lin MT. Expression of Tie-2, angiopoietin-1, angiopoietin-2, ephrinB2 and EphB4 in pyogenic granuloma of human gingiva implicates their roles in inflammatory angiogenesis. J Periodontal Res 2000;35:165-71
12. Bhaskar SN, Jacoway JR. Pyogenic granuloma—clinical features, incidence, histology, and result of treatment: report of 242 cases. J Oral Surg 1966;24:391-398.
13. Ainamo J. The effect of habitual toothcleansing on the occurrence of periodontal disease and dental caries. Suom Hammaslaak Toim 1971;67:63-70.
14. Jafarzadeh H, Sanatkhan M, Mohtasham N. Oral pyogenic granuloma: A review. J Oral Sci 2006;48:167-75.
15. Taira JW, Hill TL, Everett MA. Lobular capillary hemangioma (pyogenic granuloma) with satellitosis. J Am Acad Dermatol 1992;27:297-300.
16. Powell JL, Bailey CL, Coopland AT, Otis CN, Frank JL, Meyer I. Nd: YAG laser excision of a giant gingival pyogenic granuloma of pregnancy. Lasers Surg Med 1994;14:178-83.
17. Wang PH, Chao HT, Lee WL, Yuan CC, Ng HT. Severe bleeding from a pregnancy tumor. A case report. J Reprod Med 1997;42:359-62
18. Bouquot JE, Nikai H. Lesions of the oral cavity. In: Gnepp DR, editor. Diagnostic Surgical Pathology of Head and Neck. Philadelphia: WB Saunders; 2001. p. 141-233
19. Steelman R, Holmes D. Pregnancy tumor in a 16-year-old: Case report and treatment considerations. J Clin Pediatr Dent 1992;16: 217-8.

